



Research

Comparing Coventional and Telepathological Diagnosis in Routine Frozen Section Service

Peter Hufnagl^{1*}, Klaus-Dieter Winzer², Hans Guski¹, Jörg Hering³, Thomas Schrader⁴, Klaus Kayser¹, Cornelia Tennstedt⁵, Manfred Dietel¹

Affiliation:

1 – Institute for Pathology, Charité – Universitätsmedizin Berlin, Berlin, Germany

2 – Department of Gynecology, Charité – Universitätsmedizin Berlin, Berlin, Germany

3 – Vivantes Clinic Neukölln, Berlin, Germany

4 – University of Applied Sciences Brandenburg, Brandenburg, Germany

5 – Practice of Pathology, Mühlhausen, Germany

* Corresponding author: Prof. Dr. Peter Hufnagl; Institute of Pathology, Charité – Universitätsmedizin Berlin, 10098 Berlin.

Abstract

Aims

In a prospective randomised study the diagnostic accuracy of frozen section service of conventional and telepathological procedures was compared for routine breast surgery.

Material and Methods

In the telepathological approach the surgeon performed the gross examination and macroscopic cutting directly supervised via videoconference by a pathologist. Then a technician prepared the frozen sections and the staining. The on-line histological diagnosis was done using a remote controlled robotic microscope. The images were transferred to the computer screen of the pathologist. In the conventional mode, the pathologist himself manually performed the gross and microscopic tissue examination in the same laboratory. The material was restricted to breast specimens and the number of participating surgeons was limited in order to obtain comparable results. All in all, 81 routine frozen sections of the breast were included in the study within seven months.



Results

The overall diagnostic concordance of both approaches with the definite diagnosis based upon paraffin embedded tissue was calculated to 95,1 % (77/81 cases). The telepathology arm revealed 94,3 % (33/ 35 cases), and the conventional arm 95,7% (44/46 cases). Two cases of each arm remained uncertain. The median diagnostic time was calculated to 9 minutes in the conventional mode and to 17 minutes for telepathology. Not included are median 3 minutes for transportation and 12 minutes for slide preparation.

Discussion

Telepathology can replace successfully conventional performance of frozen section service within the same range of diagnostic accuracy.

Keywords: [Frozen section service](#), [Telepathology](#), [Remote telemicroscopy](#), [Breast surgery](#), [Randomised study](#).

Introduction

Telepathology is the practice of pathology over distances using electronic telecommunication systems [1-7]. The most frequently applied fields include expert consultation and intra-operative frozen section services [8, 9].

Frozen section services have to provide accurate microscopic diagnoses within the shortest period possible. Electronic communication can significantly diminish tissue transport time and ensure accurate diagnosis transfer between the surgical theatre and the pathology department. Different technical solutions have been used for routine diagnostic work [10-17], which can be classified into fully remote, interactive and hybrid systems [18, 19].

Several studies investigating the accuracy of frozen section diagnosis have been published [8; 12; 20-27]. The majority of publications report no statistical significant differences of diagnoses when comparing conventional diagnostic frozen section performance and telepathology application. However, the reported results differ to a certain degree, and are often not comparable in respect to the analyzed material and technical equipment. Thus, error analysis in telepathology is fairly difficult [30-32].



We herein present a randomised study that focuses on the direct comparison of telepathological and conventional frozen section service in routine breast surgery. In the telepathological arm the surgeon macroscopically cuts the specimen while being video-supervised by the pathologist, who after technical preparation and staining reads the slides using a remote-controlled robotic microscope. In the conventional arm, the pathologist himself cuts the specimen and analyses the histological section under a conventional light microscope. In this study, the surgical specimens were restricted to breast resections, and to a limited number of participating surgeons in order to obtain fairly constant inclusion parameters, and, consecutively, to obtain statistically significant results.

Material and Methods

Study Design

The study was performed during routine frozen section services in one of the three frozen section laboratories of the Institute of Pathology, Humboldt University, Berlin, based at Campus Charité Mitte.

The study was limited to breast surgery, including non-palpable lesions.

All cases included were randomly assigned to either the conventional or the telepathological arm using a dice <see Figure 1>. The surgeon and the telepathologist did not know the result of the randomisation before entering the frozen section laboratory with the specimen, and the pathologists did not know the pre-operative diagnoses.

The frozen section laboratory is located directly in the surgical theatre, thus the pathologist on duty can handle the excised specimen immediately. In case of telepathological practice an on-duty remote pathologist in the main institute was called. He performed the telepathological examination on his personal computer.

The tissue was cut using a routine cryostat and stained with hematoxylin/eosin by a medical technician. As usual, the remains of the specimen were fixed in buffered formalin, sent to the main institute of pathology, again macroscopically analysed, cut, embedded in paraffin, and thoroughly investigated for the definitive diagnosis, which served as gold standard for this study.

In both arms, the pathologist, who evaluated the frozen section, stated in addition the definitive diagnosis on the paraffin embedded tissue (PET). Cases were classified as



“concordant” or “not concordant” in respect to the discrimination between a malignant and benign disease.

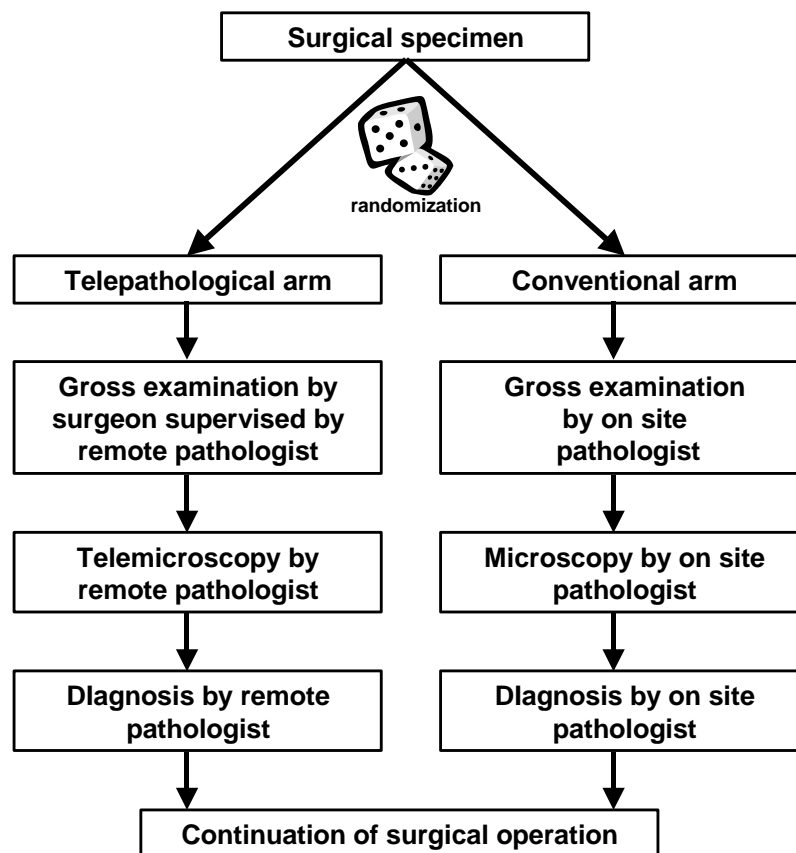


Figure 1: Study design.

Cases

All patients have been clinically examined in the Surgical Clinic, Campus Mitte, Charité, Humboldt University, Berlin. The study lasted for seven months and 81 routine frozen sections were performed.

FS	TP-FS	Total
----	-------	-------



PA, benign	21 (25,9%)	20 (24,7%)	41 (50,6%)
PA, malignant	25 (30,9%)	15 (18,5%)	40 (49,4%)
Total	46 (56,8%)	35 (43,2%)	81(100%)

Table 1: Distribution of cases between the arms of the study, PA paraffin diagnosis, FS conventional frozen section, TP-FS telepathological frozen section.

Only one block (frozen section) per tumor was taken from the tumorous lesion and macroscopically tumor-free tissue at the position nearest to the resection boundary. Additional examinations were undertaken on two patients presenting an additional on either the ipsi - lateral or contra - lateral side.

The age of the patients varied from 25 years to 87 years with a median of 58 years. The distribution of malignant and benign cases on the two arms is illustrated in Table 1. The imbalance between the number of cases in the telepathological arm (n=35) and the conventional arm (n=46) is caused by problems in study organization, especially at the beginning. The definite diagnoses of the cases in the conventional and in the telepathological arm are listed in Table 2.

	Paraffin Diagnosis	FS	TP-FS
Benign	Mastopathia	10	5
	Papilloma	1	3
	Ductal Hyperplasia	1	3
	Fibroadenoma	3	2
	Phylloid	1	1
	Others	5	6
Malignant	Invasive Ductal Carcinoma	15	12
	Invasive Lobular Carcinoma	2	1



Papillary Carcinoma	1	0
DCIS	7	2
TOTAL:	46	35

Table 2 : Differential diagnosis of the cases.

Staff

Six experienced pathologists and one surgeon specialised on breast surgery participated in the telepathology arm. All of them had already gathered experience in handling the telepathology system TPS (Leica). A total of nine pathologists only participated in the conventional arm. A medical (MD) student was always present in the frozen section laboratory. He organized the randomisation of the trial and documented all relevant events.

Feature	TPS Server configuration
Robotic microscope	Leica RXA
Macroscopic	Sony Video Presenter
Video conferencing	H.263, H.264
Static image transfer	768*576 pixels, 24 bit
Microscope camera	3 chip; Hitachi HV-C20M
Telepathology software	TPS 1.51

Table 3: Features of the TPS system.

Equipment

The telepathology system TPS 1.51(©LEICA Microsystems, Wetzlar, and Charité Berlin) was used for this study <Table 3>. It allows dynamic robotic and static telepathology. The data



transmission for telepathology is based on TCP/IP and the Local Area Network (LAN/10 Mbits/s) of the campus.

The TPS system takes the place of the server for the remote pathologists, who controlled the microscope from the client's side. The server needs specific hardware and software in order to control the microscope and the macroscope table that was equipped with a color video camera. The features of TPS client and TPS server are listed in Table 4.

Frozen section laboratory

The frozen section laboratory is located in the surgical theatre of the Charité. It can be reached within less than a minute from any surgery room. It was designed to reduce the transportation time of the surgical specimens and to facilitate communication between pathologists and

	TPS Server	TPS Client
Operating system	Windows 95	Windows 95
Processor	Pentium II 350 MHz	Celeron 900 MHz
RAM	128 MB	128 MB
PC Screen	19``Flatscreen	21``Monitor
Video conferencing	Winnov Videum	Winnov Videum
Graphic card	Multimedia	ATI 3D Rage LT Pro
Framegrabber	Matrox Meteor	-
TPS Database	Yes	Yes

Table 4: Configuration of TPS server and clients used in the study.

surgeons. The surgeon can attend the frozen section procedure and the pathologist can enter the operating room and examine the situs. Two medical technicians and one pathologist are working in this laboratory at the main surgery times. About 3,500 frozen sections were performed in 2000/2001.



The performance of on-line (frozen section) diagnosis required modifications of the TPS Server. A gross tissue examination via a video camera had to be arranged and installed in a separate (septic) room. As a consecutive, an additional monitor, keyboard and mouse were needed to offer the surgeon visual control of the image, magnification and position of the material, which was then transmitted to the remote pathologist <Figure 2>.

Gross examination and dissection

When analysing the frozen section, the pathologist was informed about the clinical record of the patient and the clinical demands. We used a conventional telephone line for the verbal communication between the surgeon and pathologist discussing the consistency, shape, topography, and colour of the material and the performed technique of excision. All parameters were documented <Figure 3>. Images of the complete and non dissected macroscopic specimen with topographical marks, measurements in centimetres, were added.




Figure 2: Telepathology workplace for gross examination and remote microscopy within the frozen section laboratory.



The resection margins were marked with colour, and the surgeon selected the tissue sample for immediate analysis under the guidance of the telepathologist. Small specimens were completely sliced by the surgeon and afterwards fixed in buffered formalin.

In addition, the remote pathologist prepared the left over-material at the next day in order to simulate the procedure in a hospital that does not possess an own institute of pathology. The tissue was pinned on a cork plate and fixated in buffered formalin for further examination.

Telemicroscopy

A global virtual map of the complete slide was created by an overview image (3x7 images with a 1,6x objective) prior to the telemicroscopy session, and a topological mapping between the overview image and images in various magnifications was realised <Figure 4>. Starting with the overview image the pathologist inspected the slide and chose position and magnification which seemed to be appropriate for stating a diagnosis. All diagnostically relevant images at different magnifications were documented. Finally, the frozen section diagnosis was sent to the surgeon, before it was archived electronically.

Documentation

All significant features of the study were documented electronically including the time needed for gross examination and dissection, slide preparation, microscopic evaluation, diagnosis, and final oral discussion. Overview images, chosen details and image positions were added.

The study design was agreed on by the ethical commission of the Charité, Medical Faculty of the Humboldt University.

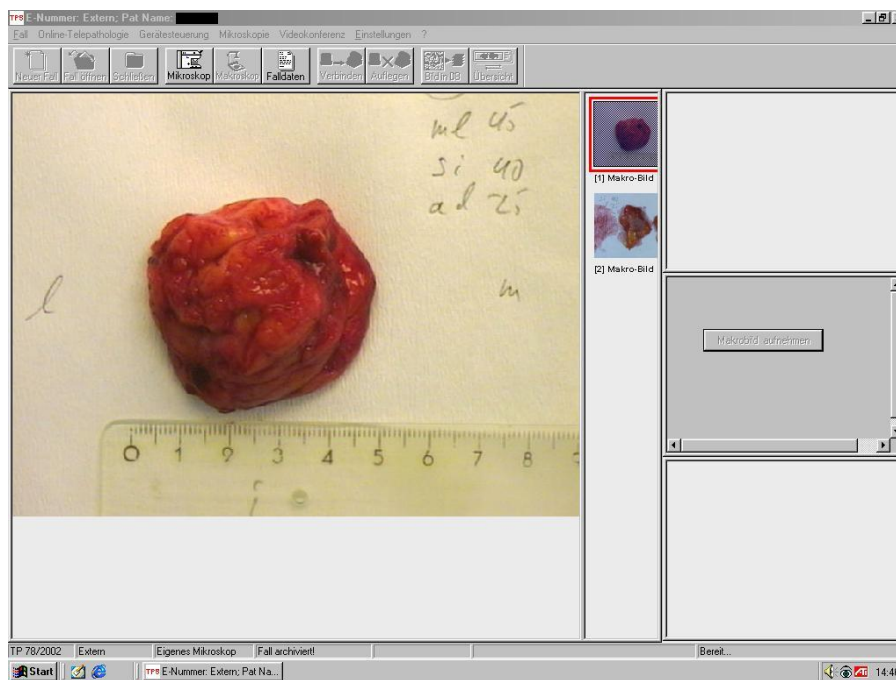
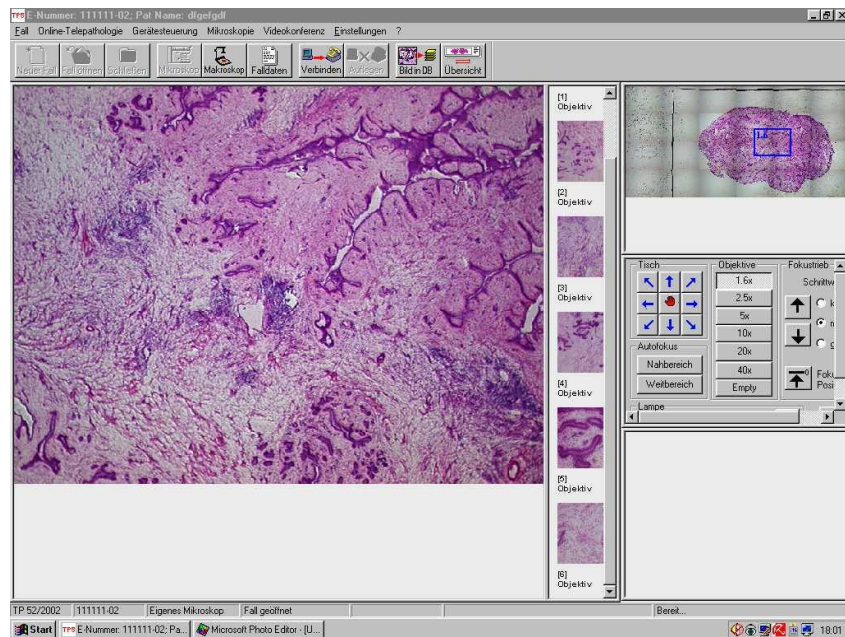


Figure 3: Screenshot, gross examination.



Figure 4: Remote microscopy, screenshot of pathologist's control window.

Results

Concordance of conventional method and telepathology

The overall concordance of the frozen section diagnoses compared to the gold standard (diagnosis based upon paraffin embedded tissue) in both arms was 95,1 % (77/81 cases). In the telepathology arm <Table 5>, we obtained a concordance of 94,3 % (33/35 cases), in the conventional arm <Table 6> a concordance of 95,7% (44 /46 cases).

Two cases in each arm remained uncertain. In the telepathology arm, one case was stated as intraductal papilloma of uncertain dignity (finally: intraductal papilloma), the second case was deferred because the remote pathologist could not sufficiently assess mitoses in the digital image (intraductal proliferations of unclear malignancy, finally: a ductal carcinoma in situ). In the conventional arm the first discordant case was stated as "suspicious of ductal hyperplasia, intraductal proliferations" (finally: ductal carcinoma in situ (DCIS I)). The second case was diagnosed as a "phylloid of unknown dignity" (finally: benign phylloid).

	TP-FS, benign	TP-FS, uncertain	TP-FS, malignant	Total
PA, benign	19	1	0	20



PA, uncertain	0		0	0
PA, malignant	0	1	14	15
Total	19	2	14	35

Table 5: Correlation between telepathological frozen section diagnosis (TP-FS) and final paraffin diagnosis (PA) for the 35 telepathology cases.

	FS, benign	FS, uncertain	FS, malignant	Total
PA, benign	20	1	0	21
PA, uncertain	0	0	0	0
PA, malignant	0	1	24	25
Total	20	2	24	46

Table 6: Correlation between conventional frozen section diagnosis (FS) and final paraffin diagnosis (PA) for the 46 conventional cases.

Time needed for conventional and telepathological diagnosis

The measure of overall time was not a reliable parameter with respect to parallel processing of cases of different urgency. Therefore, the times measured for gross examination and dissection as well as for microscopic examination were separately measured and summarized. The median time needed for the conventional frozen section was calculated 9 minutes [Table 7] that for the telepathological arm 17 minutes. This total time is shared by about 50% of gross and microscopic examination in both arms; i.e. (5min/5min) conventionally and (8 min/8.5 min) in the telepathology session. Not included are the mean times of 3 minutes for transportation and 12 minutes for slide preparation, which have been identical in both the conventional and the telepathological arm.

Time minimum	Time maximum	Time median
--------------	--------------	-------------



Macroscopy	1 min	12 min	5 min
Microscopy	0,5 min	18 min	5 min
FS total	2,5 min	27 min	9 min
Telemacroscopy	3 min	15,5 min	8 min
Telemicroscopy	3,5 min	30 min	8,5 min
TP total	6 min	42 min	17 min

Table 7: Time needed for gross examination and microscopy for conventional (FS) and telepathological (TP) frozen section diagnostic .

Discussion

We herein report the results of a prospective randomised study, which was undertaken in a specialized frozen section laboratory under routine work-load conditions. The study was restricted to breast tissue, as this material is most suitable for telepathology purposes. Breast lesions are quite frequent and surgical procedures of the breast is performed even in small hospitals that do not possess their own pathology department.

This randomized (double blind) study results in comparable deferral rates of both the conventional and the telepathology performance. A defer rate of approximately 5% has to be generally accepted in frozen section service specialized on breast specimens, a rate consistent with that reported by other authors [8; 22; 23; 26-29].

Gross examination and dissection in telepathology

Telepathology has the advantage that live-communication between the surgeon and pathologist takes place. This is not common in conventional diagnosis procedures, since the material is sent to the pathologist off line. An intensive communication is needed to replace the remote pathologist's lack of sensual information about the surgical material [16; 17]. In this study, the analysis of frozen section diagnosis of breast lesions has been chosen, as sensual information is said to be needed for these purposes. This specific requirement has been pointed out by [33-35].



During the intra-operative tissue dissection a surgeon performs the pathologist's work. Criticism [36] has claimed that only pathologists should perform the gross examination, as it does need specific experience, and, in addition, correct tissue sampling for microscopic analysis is prerequisite for reliable diagnosis. This fact requires a thorough training of the surgeon to examine the specimen, cut the material and select the diagnosis significant tissue, as well as mark the resection boundaries. This training was performed before the actual study started. To our experience, video transmission of gross findings and contemporary audio communication between the telepathology partners can compensate potential limited pathological expertise of the 'telepathology' - surgeon: No wrong tissue sampling could be noted in our study.

Time considerations

Frozen section diagnosis performed via telepathology was more time consuming compared to the conventional performance. Several authors have stated the same experience [26; 27; 29; 37]. One reason seems to be the supervision and thus more time-consuming gross examination by the telepathologist. In addition, the light microscopy via telepathology seems to require a longer diagnostic time [13]. In our experience, this disadvantage of telepathology is induced by at least three factors: a) time delay in transfer of large image components (for example overview images), b) inadequate view fields at low magnification, and c) difficulties in view field sampling, i.e., selecting the diagnostic significant position in a slide for higher magnification. These problems are probably induced by insufficient familiarity with digital images on the monitor. The reported long transfer times which have been caused by low bandwidth of electronic transfer lines combined with images acquired by high-resolution digital cameras have been solved by videoconferencing via broadband technology and virtual microscopy [16; 38-41].

Future developments



It is still difficult to forecast the future development of (frozen section applied) telepathology; however, some general remarks will probably hold true:

1. The use of telehaptic devices is under construction. These devices will allow haptic examinations of surgical specimens via telepathology, probably enhancing the speed of gross tissue examination and tissue sampling. At present, these systems can only distinguish surface characteristics such as rough, smooth, dry, soapy, and none of these systems has been tested for telepathology purposes to our knowledge. Technically, they are not fully developed and do not yet possess features appropriate for clinical routine [38-40].
2. Tissue examination via a conventional light microscope still possesses some features of a 3-D image which is lost in digital diagnostic pathology. This is caused by changing the focus plane manually. There are some efforts ongoing to improve the diagnostic assessment of a remote pathologist by transmission of (re-constructed) histologic 3D images. First successful trials have already been reported in telepresence (telesurgery) [42-48].
3. The digitalization of tissue – based diagnosis will also contribute to performance changes in frozen section services, for example by use of so – called diagnosis assistants and automated image content analysis [49-51].

References

1. [Weinstein, L.J., et al., Static image analysis of skin specimens: the application of telepathology to frozen section evaluation. Hum Pathol, 1997. 28\(1\):30-5.](#)
2. [Weinstein, M.H. and J.I. Epstein, Telepathology diagnosis of prostate needle biopsies. Hum Pathol, 1997. 28\(1\):22-9.](#)
3. [Kayser, K., Telepathology, images, and multimedia archives. Adv Clin Path, 1998. 2\(2\):157.](#)
4. [Kayser, K., Telepathology in Europe. Anal Cell Pathol, 2000. 21\(3-4\): 95-6.](#)
5. [Kayser, K., Interdisciplinary telecommunication and expert teleconsultation in diagnostic pathology: present status and future prospects. J Telemed Telecare, 2002. 8\(6\): 325-30.](#)
6. [Kayser, K., M. Drlicek, and W. Rahn, Aids of telepathology in intra-operative histomorphological tumor diagnosis and classification. In Vivo, 1993. 7\(4\): 395-8.](#)



7. [Kayser, K., P. Fritz, and M. Drlicek, Aspects of telepathology in routinary diagnostic work with specific emphasis on ISDN. Arch Anat Cytol Pathol, 1995. 43\(4\): 216-8.](#)
8. [Cross, S.S., T. Dennis, and R.D. Start, Telepathology: current status and future prospects in diagnostic histopathology. Histopathology, 2002. 41\(2\): 91-109.](#)
9. [Gu, J., Recent advances in telepathology. Cell Vis, 1998. 5\(1\): 62-6.](#)
10. [Eide, T.J. and I. Nordrum, Current status of telepathology. Apmis, 1994. 102\(12\): 881-90.](#)
11. [Eide, T.J., et al., \[Use of telecommunications in pathology and anatomy services\]. Tidsskr Nor Laegeforen, 1991. 111\(1\): 17-9.](#)
12. [Adachi, H., et al., Frozen-section services by telepathology: experience of 100 cases in the San-in District, Japan. Pathol Int, 1996. 46\(6\): 436-41.](#)
13. [Baak, J.P., P.J. van Diest, and G.A. Meijer, Experience with a dynamic inexpensive video-conferencing system for frozen section telepathology. Anal Cell Pathol, 2000. 21\(3-4\): 169-75.](#)
14. [Banach, L., et al., Dynamic active telepathology over National Health Laboratory service network, South Africa: feasibility study using Nikon Coolscope. Diagn Pathol, 2008. 3 Suppl 1: S3.](#)
15. [Baruah, M.K., The practice of telepathology in India. J Postgrad Med, 2005. 51\(4\): 316-8.](#)
16. [Hufnagl, P., et al., Comparison of different telepathology solutions for primary frozen section diagnostic. Anal Cell Pathol, 2000. 21\(3-4\):161-7.](#)
17. [Hufnagl, P. and K. Schluns, \[Virtual microscopy and routine diagnostics. A discussion paper\]. Pathologe, 2008. 29 Suppl 2: 250-4.](#)
18. [Weinstein, R.S., et al., Telepathology overview: from concept to implementation. Hum Pathol, 2001. 32\(12\): 1283-99.](#)
19. [Weinstein, R.S., et al., Overview of telepathology, virtual microscopy, and whole slide imaging: prospects for the future. Hum Pathol, 2009. 40\(8\):1057-69.](#)
20. [Fronza, C.F. and H. Fronza, Jr., Telepathology: diagnostic aid, second medical opinion and validation of the diagnostic efficiency. AMIA Annu Symp Proc, 2007: 958.](#)
21. [Fujita, M., et al., The validity of intraoperative frozen section diagnosis based on video-microscopy \(telepathology\). Gen Diagn Pathol, 1995. 141\(2\): 105-10.](#)



22. [Dunn, B.E., et al., *Use of telepathology for routine surgical pathology review in a test bed in the Department of Veterans Affairs*. Telemed J, 1997. 3\(1\):1-10.](#)
23. [Dunn, B.E., et al., *Combined robotic and nonrobotic telepathology as an integral service component of a geographically dispersed laboratory network*. Hum Pathol, 2001. 32\(12\):1300-3.](#)
24. [Dunn, B.E., et al., *Routine surgical telepathology in the Department of Veterans Affairs: experience-related improvements in pathologist performance in 2200 cases*. Telemed J, 1999. 5\(4\): 323-37.](#)
25. [Dunn, B.E., et al., *Robotic surgical telepathology between the Iron Mountain and Milwaukee Department of Veterans Affairs Medical Centers: a 12-year experience*. Hum Pathol, 2009. 40\(8\):1092-9.](#)
26. [Wellnitz, U., et al., *Reliability of telepathology for frozen section service*. Anal Cell Pathol, 2000. 21\(3-4\): 213-22.](#)
27. [Wellnitz, U., et al., *The validity of telepathological frozen section diagnosis with ISDN-mediated remote microscopy*. Virchows Arch, 2000. 437\(1\):52-7.](#)
28. [Della Mea, V., et al., *Combining dynamic and static robotic telepathology: a report on 184 consecutive cases of frozen sections, histology and cytology*. Anal Cell Pathol, 2000. 20\(1\): 33-9.](#)
29. [Della Mea, V. and F. Demichelis, *Accuracy of telepathology*. J Telemed Telecare, 2004. 10\(2\): 123-4; author reply 124.](#)
30. [Odze, R.D., et al., *Interobserver variability in the diagnosis of ulcerative colitis-associated dysplasia by telepathology*. Mod Pathol, 2002. 15\(4\): 379-86.](#)
31. [Odze, R.D., et al., *Variability in the diagnosis of dysplasia in ulcerative colitis by dynamic telepathology*. Oncol Rep, 2006. 16\(5\): 1123-9.](#)
32. [Obstfelder, A., *Social dilemmas in a telemedicine network: experience with the implementation of the Norwegian Pathology Network*. J Telemed Telecare, 2003. 9 Suppl 1: S29-30.](#)
33. [Fónyad, L., L. Piros, and G. Arató, *How do I diagnose Primary neuroendocrine tumor of the breast*. Diagnostic Pathology, 2016. 1: 101.](#)
34. [Kunze, K., *Limits of Morphological Diagnostics*. Diagnostic Pathology, 2016. 2:103.](#)
35. [Leong, F.J., et al., *Clinical trial of telepathology as an alternative modality in breast histopathology quality assurance*. Telemed J E Health, 2000. 6\(4\):373-7.](#)



36. [Stolte, M., \[Rapid biopsy diagnosis per "telepathology". Risk of transgressing specialty boundaries\]. Pathologe, 1999. 20\(6\): 373.](#)
37. [Kayser, K., et al., How to implement digital pathology in tissue-based diagnosis \(surgical pathology\)? Diagnostic Pathology, 2015. 1: 89.](#)
38. [Schwarzmann, P., B. Binder, and R. Klose, Technical aspects of telepathology with emphasis on future development. Anal Cell Pathol, 2000. 21\(3-4\):107-26.](#)
39. [Schwarzmann, P., et al., Field test to evaluate telepathology in telemedicine. J Telemed Telecare, 1996. 2 Suppl 1: 17-20.](#)
40. [Schwarzmann, P., et al., Telemicroscopy stations for telepathology based on broadband and ISDN connections. Arch Anat Cytol Pathol, 1995. 43\(4\):209-15.](#)
41. [Felten, C.L., et al., Virtual microscopy: high resolution digital photomicrography as a tool for light microscopy simulation. Hum Pathol, 1999. 30\(4\):477-83.](#)
42. [Wilbur, D.C., Digital cytology: current state of the art and prospects for the future. Acta Cytol. 55\(3\): 227-38.](#)
43. [Wilkinson, D.S., The role of technology in the clinical laboratory of the future. Clin Lab Manage Rev, 1997. 11\(5\):322-30.](#)
44. [Yagi, Y., Telepathology support for the Mediterranean Institute for Transplantation and Advanced Specialized Therapies. Telemed Today, 2000. 8\(3\): 6, 16-7.](#)
45. [Yagi, Y., et al., The First Congress of the International Academy of Digital Pathology: digital pathology comes of age. Anal Cell Pathol \(Amst\). 35\(1\): 1-2.](#)
46. [Zwonitzer, R., et al., Virtual 3D microscopy in pathology education. Hum Pathol. 41\(3\): 457-8.](#)
47. [Schlag, P.M., et al., Telemedicine: the new must for surgery. Arch Surg, 1999. 134\(11\): 1216-21.](#)
48. [Leong, F.J. and J. McGee, Robotic Interactive Telepathology in proficiency testing/quality assurance schemes. Electronic Journal of Pathology and Histology 2001. 7: 2.](#)
49. [Kayser, K., et al., Contribution of Measurement to morphologic Diagnostics. Diagnostic Pathology, 2016.2: 105.](#)
50. [Kayser, K., et al., The concept of entropy in histopathological diagnosis and targeted therapy. Diagnostic Pathology, 2015. 1: 97.](#)



51. [Sharma, H., et al., A review of graph-based methods for image analysis in digital histopathology. Diagnostic Pathology, 2015. 1:61.](#)