



Proceedings

SY08.01 | Image Analysis II

USE OF DIGITAL IMAGE ANALYSIS FOR OUTCOME PREDICTION IN BREAST CANCER

I. Roxanis*¹, R. Colling²

¹Oxford University Hospital and NIHR Biomedical Research Centre, Oxford, United Kingdom, ²University of Oxford, Oxford, United Kingdom

Introduction/ Background

Breast cancer is the most common cancer in the UK. Although 10 year survival has increased over last decades, significant improvement is still needed. Clinical management decisions are largely dependent on assessment of histological features. The traditional approach to histopathological assessment has been the expert manual reporting of cases as viewed with a light microscope and has remained virtually unchanged since 1928, with minor modifications that have led to the current routinely applied semi-quantitative tumour grading system. However, the abundance of information within the tumour microenvironment is not reflected in the traditionally evaluated histological features, and there remain morphological features with prognostic potential that have previously been beyond investigation by traditional manual microscopic means. Tumour prognosis is closely related to metastasis, a complex process involving tumour cell migration through the stromal microenvironment before entering the lymphovascular compartment. Tumour/stromal interaction is crucial in the process and represents a potential candidate for therapeutic intervention. This interaction is partly affected by the pattern of tumour migration, revealed in the tumour architecture, and partly by the stromal response.

Aims

Our working hypothesis for the proposed study framework was that, with the application of digital image analysis technology, previously unquantifiable tumour architectural and microenvironmental features can be rigorously assessed in detail and tested as potential prognostic parameters. Quantified features included tumour extracellular particles at the tumour-stroma interface, tumour infiltrating lymphocytes, tumour nest perimeter, number, size and shape. The selected prognostic parameter was axillary lymph node metastasis.

Methods

Our initial study included diagnostic core biopsies from 19 HER2 positive breast cancers, with approximately equal number of ER strongly positive or weakly positive/ negative cases. Her2 immunohistochemistry allowed rigorous segregation of epithelial elements. Immunostained sections were digitised using a Hamamatsu scanner and x10 magnification consecutive segments from .ndpi files were captured as .jpeg files and analysed using Fiji (Image J), a public domain image processing program. The entirety of each core was examined in all cases. Several native Fiji Functions and Fiji plugins, including Trainable Weka Segmentation, Colour Segmentation and Colour Deconvolution were employed in different combinations for different types of analysis. The analysis is currently being expanded to a large set of digitized breast cancer tissue microarray (TMA) slides which have been stained with cytokeratin to highlight tumour cells. The set includes breast cancer cases from all molecular subtypes and is linked with detailed histological and outcome data.

Results

Increased number of extracellular particles at the tumour-stroma interface and decreased number of tumour-infiltrating lymphocytes were significantly associated with axillary lymph node metastasis ($p=0.0062$ and $p=0.0154$ respectively). Combination of the two parameters increased further the strength of the association ($p=0.0011$). Increased total tumour nest perimeter, tumour nest number and tumour nest shape irregularity were also significantly associated with axillary lymph node metastasis ($p=0.0288$, $p=0.0085$ and 0.0203 respectively).



Data from the analysis of TMAs are currently analyzed and will be presented.

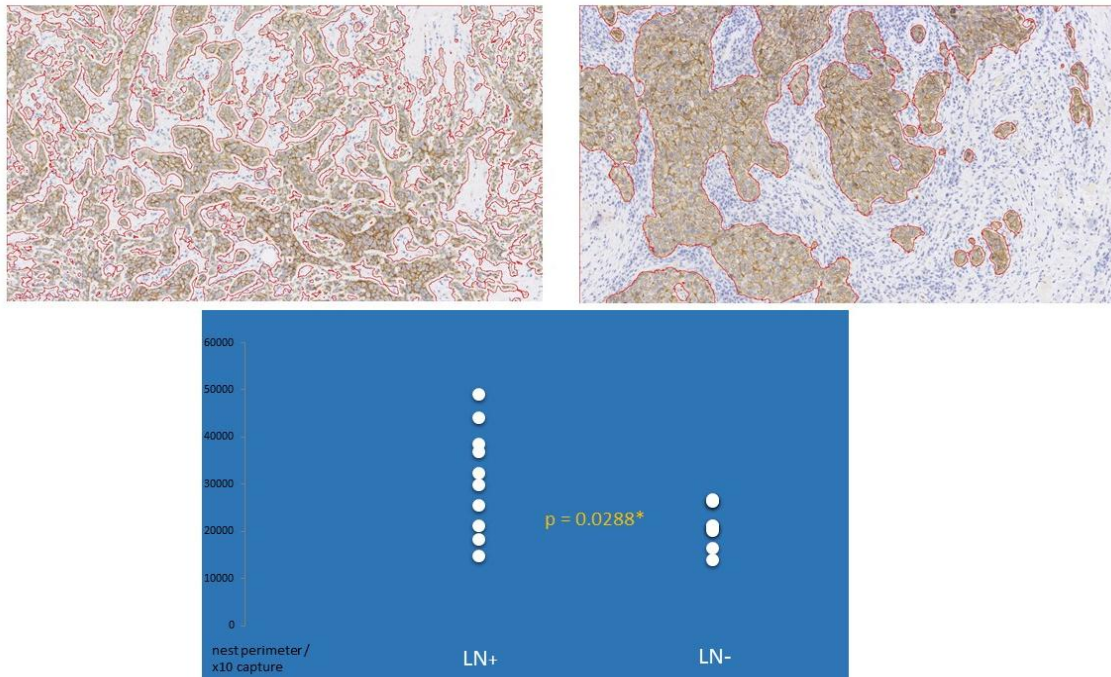


Figure 1.

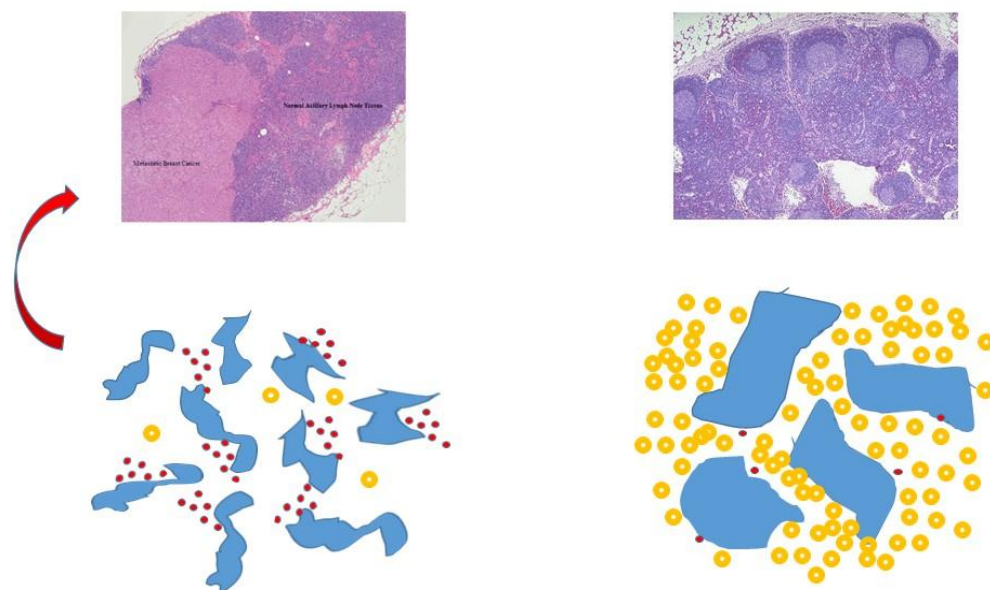


Figure 2.