



How do I diagnose *Rectum carcinoma Metastases into the Lung*

Klaus Kayser*, Stephan Borkenfeld, Krasi Serguieva, Gian Kayser

Affiliation: Institute of Pathology, Charite, Berlin, Germany

Email: Klaus.kayser@charite.de

Differential diagnoses: Primary Adeno Carcinoma, Blastoma, Germ Cell Tumor

Side findings: Anthracosis, Atypical Alveolar Hyperplasia

Abstract

This mild smoking women (7 pack years at pulmonary surgery) developed a well differentiated rectum carcinoma (pT3N1M0G1R0) at the age 54 years. Four years later two pulmonary lesions were detected suspicious for lung metastases. Two intrapulmonary metastases were resected. No indication for additional metastases seven years after wedge resection of pulmonary metastases.

Virtual Slides: www.diagnosticpathology.eu/vs/2015_1_64/

Anamnesis / History

The patient was a mild smoker (7 pack years at time of lung surgery). The rectum carcinoma was detected due to bleedings. The well differentiated rectum carcinoma could be completely excised (tumor stage pT3N1G1M0R0). Four years later two lung lesions were seen and resected by wedge resections. Unsuspicious post surgical course. The patient is still alive 7 years after lung surgery.

Gross - microscopic findings

A 80 * 65 * 50 mm large, 33.5 gr heavy lingula displaying with a 31 * 28 * 28 mm grayish white tumor mass was excised as well as a 100 * 70 * 58 mm large, 35 gr heavy segment S9 displaying with a necrotic, grayish - red - pink, 26 * 26 * 24 mm large tumor mass by wedge resection. Tumor distance from the resection boundaries 15 mm (lingula) and 5 mm (segment S9). Some thickened artery walls were seen in the lung specimens. No metastases in 4 excised lymphnodes (No 5, 10, 11, 12).

Microscopy

Well differentiated tumor structures built of large tumor cells with polar oriented nuclei and PAS negative cytoplasm. Necrotic areas in both lesions, weak inflammatory response of host tissue, papillary and tubular structures. Only a few mitotic figures. The vessel walls were hyalinized, the lumen was narrowed by endothelial proliferations.



Expression of markers

Not applied

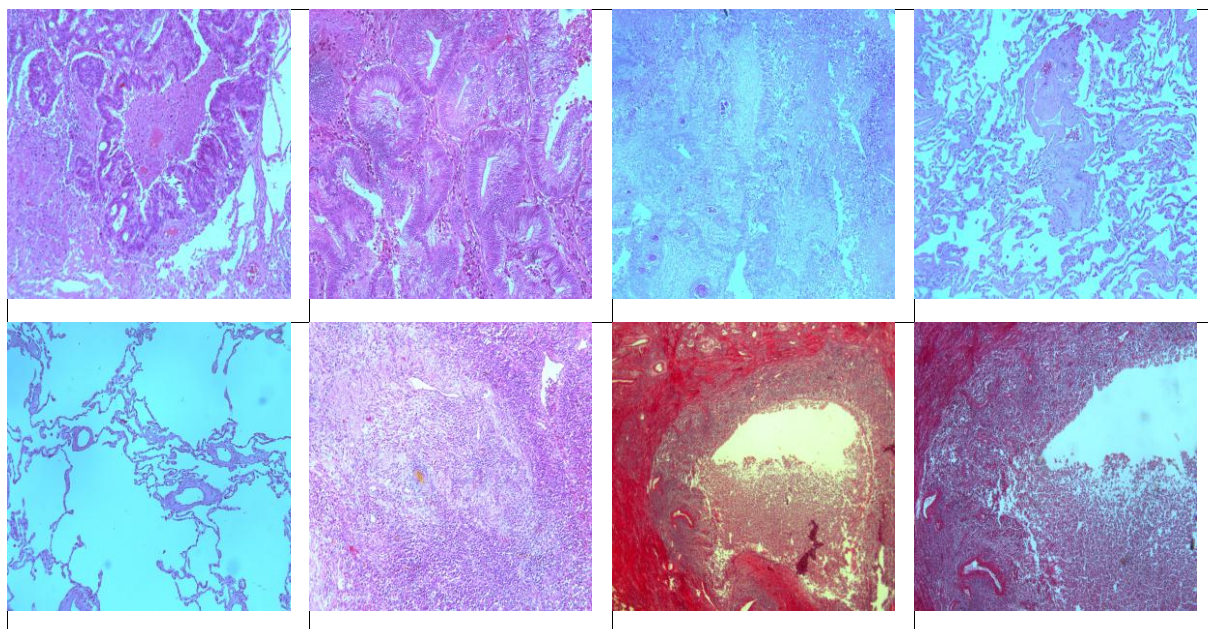
Discussion

Intrapulmonary metastases of rectum carcinomas occur between 2 - 7 years after resection of the primary carcinoma. They can be mistaken for primary well differentiated lung adenocarcinomas as well as rare pulmonary tumors such as blastomas or germ cell tumors, or squamous cell carcinomas. Mutations in the RAS and P13K pathways of both primary and metastases have been reported [1]. Metastases of rectum carcinomas are usually located in the peripheral lung tissue in contrast to metastases of breast carcinomas which might display with centrally intra bronchial tumor growth. Successful pre-surgical combined multimodality therapy has been reported in a few cases of meta-synchronous metastases [2].

Hallmarks of Diagnosis

Clinical history, well differentiated tumor structures, centrally necrotic altered lesions, weak inflammatory response of host tissue.

Images (for full size images see supplements)





Keyword - Diagnosis: [lung metastasis of rectum carcinoma](#)

Keyword - differential diagnosis: [blastoma](#)

Keyword - side findings: [anthracosis](#)

Keyword - organ: [lung](#)

Keyword - methods: [wedge resection](#)

Keyword - others: [multimodality therapy](#)

Online References (PubMed)

1. Lan YT, Jen-Kou L, Lin CH, Yang SH, Lin CC, Wang HS, Chen WS, Lin TC, Jiang JK, Chang SC. [Mutations in the RAS and PI3K pathways are associated with metastatic location in colorectal cancers.](#) J Surg Oncol. 2015 Jun;111(7):905-10. doi: 10.1002/jso.23895.
2. Yamada T, Kim C, Nakagawa T, Hiraoka K, Konishi K, Endo S, Okuyama M, Oda K, Hayakawa M, Yamauchi A, Nishijima J. [\[Report of a successful case of multidisciplinary therapy for a patient with lung and liver metastasis from rectal adenocarcinoma\].](#) Gan To Kagaku Ryoho. 2014 Nov;41(12):2068-70. Japanese. PMID: 25731425